

Malrotation and Volvulus in Infancy and Childhood

By A.J.W. Millar, H. Rode, and S. Cywes
Rondebosch, South Africa

The subject of malrotation and midgut volvulus in infancy and childhood is reviewed from the perspective of experience with 138 patients evaluated in a published series and a further 82 cases seen since. Embryology, historical aspects, clinical presentation, investigation, surgery, and outcome are discussed. The diagnosis of malrotation and volvulus should always be kept in mind when assessing any infant or child with symptoms of vomiting and pain, particularly when the vomiting is bile-stained. The diagnosis cannot be excluded if diarrhea is present, when clinical findings are bland, or even with normal abdominal radiographs. A contrast meal and follow-through should be done and, if correctly interpreted, should be diagnostic. Ultrasound examination may be helpful but is not secure enough to exclude the diagnosis. Laparotomy or laparoscopy is the only way to be sure. Malrotation with its propensity for volvulus is truly a time bomb lying within.

© 2003 Elsevier Inc. All rights reserved.

ABNORMALITIES OF ROTATION and fixation of the intestines are of intense interest to the pediatric surgeon, as it is a frequently encountered condition and most surgeons will know of at least one case where diagnosis was delayed or not even considered, with dire consequences for that unfortunate patient.¹ However, a wide spectrum of opinion exists among pediatric surgeons regarding diagnosis and management, as reported in a recent survey of North American pediatric surgeons.²

The description of the embryological development of the intestine and the process whereby a single tubular structure supplied by three arteries comes to take up the anatomical arrangement we all know so well was published in the 19th century.³ The clinical presentation and surgical management were beautifully described by Dott, Ladd, and Waugh in the first half of the last century with little subsequent progress made, apart from the recent influence of new technology in the form of diagnostic ultrasound and laparoscopic surgery.³⁻⁸ However, controversies still exist, particularly with regard to management of the incidentally observed malrotation.^{1,9} Where anomalies of rotation and fixation of the midgut result in a narrow base to the small bowel mesentery, volvulus may occur, often with catastrophic consequences. While mortality from midgut strangulation has decreased in recent years, a perusal of indications for intestinal transplantation will attest to the fact that diagnosis is missed in a significant number of cases by the primary care physician or pediatrician, and occasionally by the surgeon whose unhappy task it may be to expose the twisted infarcted gut, which portends death or a life of misery

from short-gut syndrome.⁹⁻¹¹ In this article, the embryology, pathology, patterns of clinical presentation, and current approaches to diagnosis and management are reviewed.

EMBRYOLOGY^{3,4,12}

The formation of the digestive system is initiated within 2 weeks of fertilization and by the third and fourth weeks the flat embryonic disc is transformed into a cylindrical embryo attached to the yolk sac by a narrow stalk. The infolded endoderm destined to become the primitive gut forms a single tube, which in its midportion communicates with the yolk sac by the vitellointestinal duct. In the abdominal cavity the upper layer of the mesoderm becomes the parietal peritoneum and the lower layer envelops the gut to form the mesenteries, and this envelopment by mesoderm results in the longitudinal attachment of the gut within which run the blood vessels. At the beginning of the fifth week, the arteries supplying the midgut [superior mesenteric (SMA)] and hindgut (inferior mesenteric), appear. The extremities of the midgut become fixed to the posterior abdominal wall at the duodenum above and the so-called colic angle below. These two points are quite close together, forming the duodenocolic isthmus. Rapid elongation of the midgut causes it to bend ventral in the midplane to form a U loop with the superior mesenteric artery as its axis and the yolk stalk attached to its apex. The segments of bowel above and below the SMA are termed the prearterial and postarterial limbs of the intestinal loop. The loop elongates so rapidly that it is extruded into the umbilical cord, forming a temporary physiological hernia. Succeeding changes include enlargement, elongation, and return of hernial contents, rotation and final placement and fixation of the fetal gut. The classical description of a first, second, and third stage of rotation has been recently contested by Kluth and colleagues, studying rat embryos, who suggest that anomalies of rotation result from degrees of localized growth failure of the duodenum, which

From the Department of Paediatric Surgery, School of Child and Adolescent Health, University of Cape Town and Red Cross Children's Hospital, Rondebosch, South Africa.

Address reprint requests to A.J.W. Millar, Department of Paediatric Surgery, School of Child and Adolescent Health, University of Cape Town and Red Cross Children's Hospital, Rondebosch, South Africa.

© 2003 Elsevier Inc. All rights reserved.

1055-8586/03/1204-0003\$30.00/0

doi:10.1053/j.sempedsurg.2003.08.003

is the part of the gut directing anatomical position on "return" of the midgut into the abdomen.¹³ It is true that there is no evidence of rotation as such and that the changes in position are likely a result of periods of differential growth. However, the classical description does help us to interpret the pathological anatomical findings.

ANOMALIES OF ROTATION AND FIXATION^{4,12}

Complete failure of rotation is rare but has been observed in infants with exomphalos, where small and large bowel may have a common longitudinal mesentery. This by itself is clinically unimportant. This could also be regarded as due to nonrotation. The principal errors during the second stage of rotation are nonrotation, reversed rotation, and malrotation. Nonrotation is thought to occur when an abnormally lax umbilical ring has allowed the midgut to return en masse without rotating. The first and second parts of the duodenum are situated normally but the third and fourth parts descend vertically downward along the right side of the superior mesenteric artery. The small bowel lies chiefly to the right and the colon doubled on itself to the left of the midline. If there is also failure of fixation, which is often the case, the entire midgut loop may be suspended in the abdominal cavity by a narrow pedicle, which predisposes the whole midgut to volvulus. We have seen such a case in an infant with a small umbilical hernia and Beckwith Wiedeman syndrome. Reversed rotation is where the cecum and colon take up a position behind the superior mesenteric vessels and the duodenum crosses anterior to it. Malrotation is when the normal process of rotation is arrested or deviated at various stages. The most frequent is when the cecum has failed to reach the right iliac fossa and lies in a subhepatic or central position. This may also be associated with anomalous fixation of the gut, usually with dense fibrous bands extending from the cecum and right colon across the duodenum to the retroperitoneum of the right upper quadrant. Although duodenal obstruction has been attributed to these bands, this is, in our experience, a rare occurrence.¹⁴⁻¹⁶ Duodenal obstruction, when it occurs, is almost invariably caused by torsion at the base of the midgut mesentery, as there has also been failure of fixation as well, allowing the whole midgut to lie free within the abdomen.¹⁴ Bands may also form between the right colon and the duodenum drawing them closer together again predisposing towards volvulus.^{5,12,14} A duodenal web may occasionally be encountered.

Derangements of the third stage of rotation include delayed or deficient fixation, which may predispose to midgut and caecal volvulus and intussusception (Waugh's syndrome).^{6,17,18} The internal hernias are also a

group of anomalies now believed to result from incomplete fixation of the mesentery.¹²

Premature or excessive fixation may be responsible for kinking of the duodenum as described by Ladd in his later article.¹⁵ Anomalies such as intestinal atresia, diaphragmatic hernia, abdominal wall defects, Hirschsprung's disease, situs inversus, and cardiovascular defects may be causative in some instances and are present in more than 50% of cases in some series.^{1,19,20}

CLINICAL MANIFESTATIONS OF ANOMALOUS ROTATION

The pathologic effects of anomalies of rotation arise from excessive mobility, compression, or kinking of bowel and predisposition to torsion, volvulus, and intussusception. Most present in infancy but up to 20% develop symptoms after 1 year of age.^{12,14-20}

Antenatal midgut volvulus leading to infarction and absorption of much of the jejunum is thought to be the cause of Type 111b intestinal atresia, where there is an upper jejunal atresia just distal to the ligament of Treitz.²¹ A varying length of distal ileum is supplied by a single vessel, an extension of the right colic artery (Fig 1). Contrast enema usually demonstrates the cecum lying in the central abdomen and excludes a second colonic atresia. The right colic artery arises from the middle colic or proximal ileocolic arteries, which, as the first large branches of the SMA, have survived the presumed torsion of the SMA, which has disappeared distal to the middle colic branch.

Overall about 50% present in the first week of life and more than 60% before the end of the first month; the most frequent symptom being bile-stained emesis.¹⁴ Males are slightly more frequently affected than females. In the classic Ladd's syndrome (undescended cecum, malfixation of the mesentery, and bands crossing the duodenum), the clinical features in the neonate are indistinguishable from those of duodenal stenosis with vomiting, which is usually green or yellow in color, and upper abdominal distension, which resolves on aspiration by nasogastric tube. Pain or irritability is not a prominent clinical feature in the neonate, but is a clinical feature in the toddler and older child.¹⁴ The abdomen is soft and nontender to palpation until strangulation of bowel has developed, when it becomes distended and tender and stools bloodstained.¹⁴ Abdominal radiographs may show a dilated duodenum with a fluid level and some gas in the distal bowel, but can be interpreted as normal in 20% (Fig 2A, B). Dott emphasized the point that gas is rarely trapped distal to the point of proximal obstruction.⁴ Barium enema examination is unreliable in confirming the diagnosis, as the position of the cecum is so variable.²² Multiple air-fluid levels in dilated bowel loops are omi-

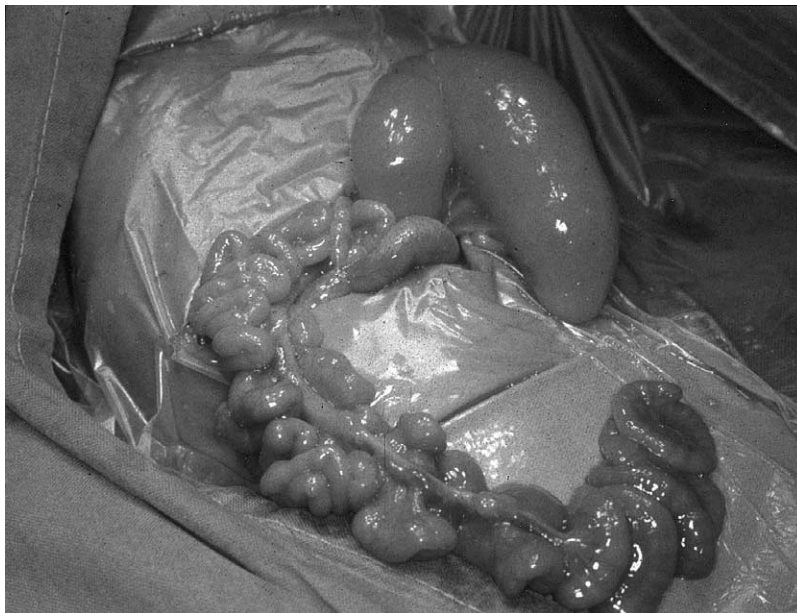

Fig 1. Type IIIb Intestinal atresia. Note the proximal jejunal atresia, centrally placed cecum and long segment of ileum with tenuous vascular supply and venous congestion arising from the right colic vessels, presumably caused by antenatal midgut volvulus.

nous signs and usually indicate established gut infarction (Fig 3). A contrast meal is more accurate in defining the size, shape, rotation, and presence of obstruction in the duodenum or upper jejunum²² (Figs 2, 4B). Where volvulus is present the plain films reveal a paucity of gas shadows and a dilated stomach (Fig 4A). The contrast examination with a volvulus will show a dilated duodenum with often a typical corkscrew appearance projecting forward away from the posterior abdominal wall on an oblique view (Fig 4B). Volvulus in the neonatal period, especially the premature baby, may occur without malrotation because of the laxity of tissue in the first weeks of life, less posterior fixation, and a relatively narrow base to the midgut mesentery.²³

Assessment of the position, relative relationship of the superior mesenteric vessels by ultrasound and Doppler flow characteristics, and reversal of that position in volvulus may be useful adjuncts but are not sufficiently accurate to confidently exclude malrotation or volvulus.^{7,24,28} Laparoscopy may also be used to confirm or exclude the diagnosis and, in selected cases, may even be used for treatment.^{7,8}

Diagnosis in the older child becomes more difficult, as the differential diagnostic spectrum of symptoms of abdominal pain, vomiting, and a disturbance of stooling pattern is so much greater (Fig 5A, B).^{9,14,15,20} Pain and vomiting are the major symptoms, but vomiting is initially non-bile-stained in up to 50% of cases. Stooling pattern varies and diarrhea, recorded in 16% in our series and 23% in another, may be confusing.^{14,20} Stuttering attacks of pain and vomiting resulting from intermittent

torsion are not uncommon. With chronicity there is a danger that a diagnostic label such as “cyclical vomiting” or “abdominal migraine,” or “psychogenic” is attached to the patient, as physical findings are usually minimal, inhibiting intellectual vigor when “another attack” occurs.^{1,9,14,25,27} Gastroesophageal reflux may frequently be observed on contrast meal examination but observation of the gastroesophageal reflux should not limit the scope of the investigation as the duodenal anatomy must be visualized before completion of the study.²⁸

Although more than 60% have an acute onset, chronicity of symptoms for more than a year is a frequent finding, 12% in our series.^{14,29} This may be associated with failure to thrive, especially when chronic torsion of the root of the mesentery leads to lymphatic obstruction and malabsorption, even jaundice.³⁰ Chylous ascites has been seen even in the neonatal period when it may be noted at herniotomy.³¹ This finding should prompt a request for a contrast meal to exclude malrotation and volvulus. Reliance on radiography to confirm the diagnosis where the significance of findings have not been appreciated or correctly interpreted has led to delay in diagnosis (Fig 2A, B). This usually relates to the configuration of the third and fourth part of the duodenum, which should cross the midline and ascend posteriorly to the same level as the first part on the anterior/posterior view (Fig 5B). Differential caliber and to-and-fro duodenal peristalsis is also suggestive of intermittent obstruction. One of our cases was investigated and observed for 7 months with malabsorption, protein-losing enteropathy, and failure to thrive. Vomiting was only

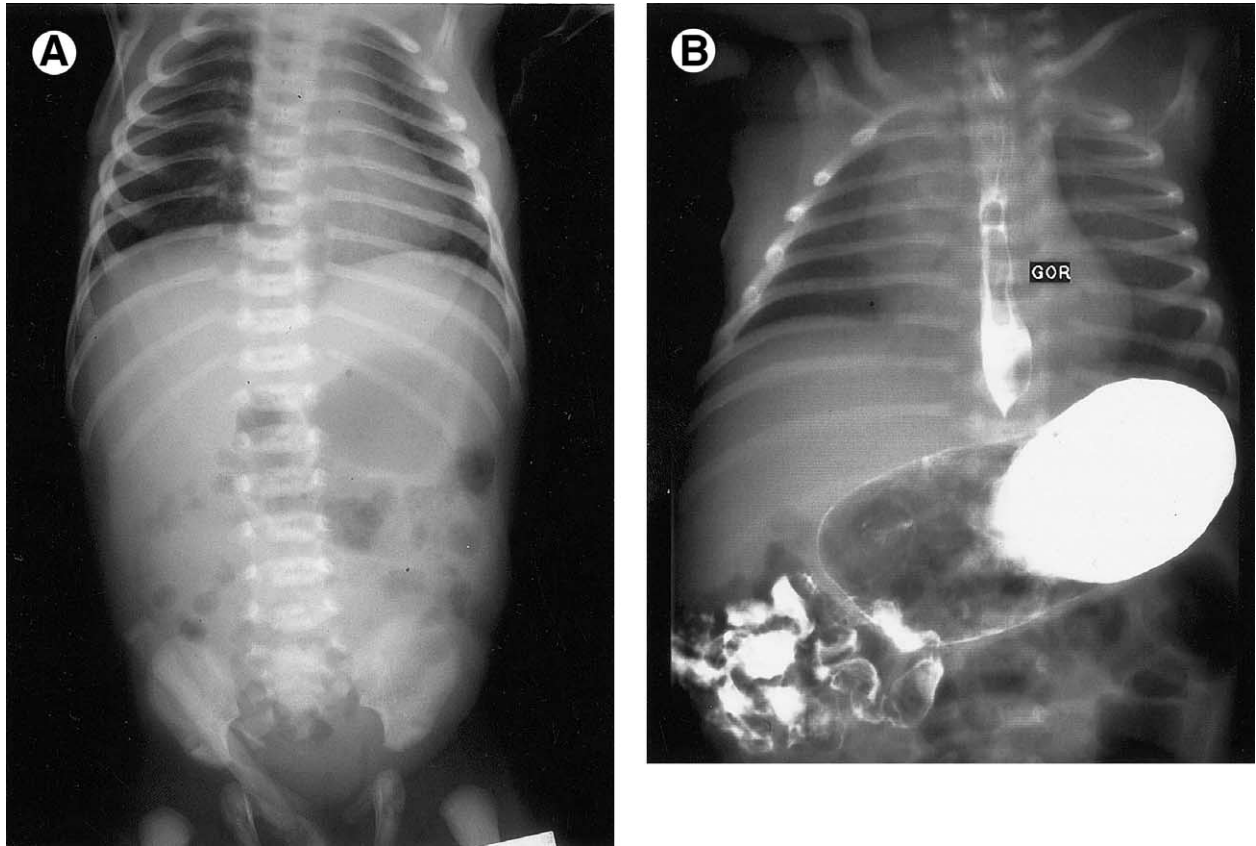


Fig 2. (A) Abdominal radiograph of a week-old infant with a history of vomiting, not obviously bile-stained and loose stools, which was reported as normal. Persistent vomiting prompted further investigation with a contrast meal (B). Note gastroesophageal reflux but a dilated stomach, some delay in gastric emptying, a malrotated duodenum and small bowel on the right side. Laparotomy confirmed malrotation with Ladd's bands and 270-360° midgut volvulus.

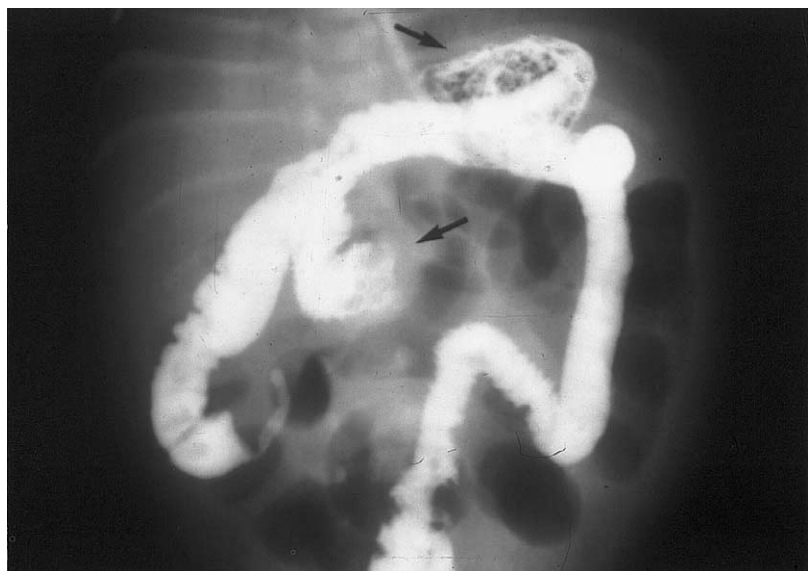

Fig 3. Radiograph of contrast examination of an infant with delayed presentation of bilious vomiting. The abdomen was distended and tender. Note the obstruction of stomach and duodenum (arrows), the "high" cecum on contrast enema and the gas-filled loops of small bowel. Midgut volvulus with ischemic infarction was confirmed at laparotomy.

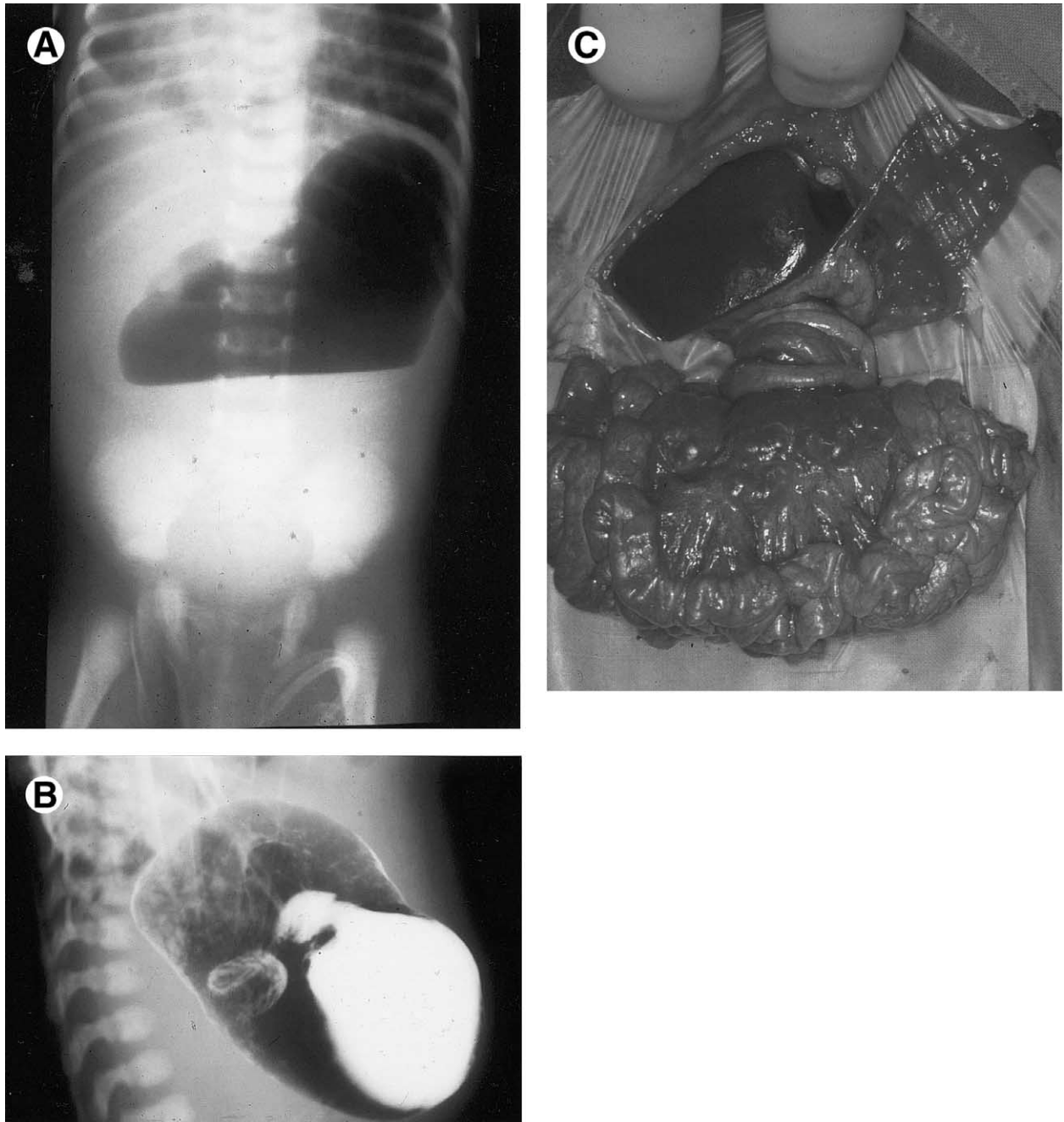


Fig 4. (A) Erect abdominal radiograph of a 1-month-old infant presenting with 36 hours of bilious vomiting. A previous episode the week before had settled with conservative management. (B) Note the near-complete duodenal obstruction with the typical corkscrew appearance of the duodenum on contrast meal (oblique view). (C) Laparotomy revealed 720° clockwise midgut volvulus with lymph node enlargement but otherwise healthy bowel.

occasional. A contrast meal had shown a “low-lying” duodenum but no obstruction. Technetium-^{99m} scan showed intense uptake in the central abdomen, which at laparotomy was due to partial lymphatic and venous obstruction from a 360° midgut volvulus (Fig 6).

It is not surprising that delay in diagnosis and surgical intervention remains the rule rather than the exception, even in the neonatal period, and the significance of symptoms, particularly of bilious vomiting, is not generally appreciated.¹⁴ It is indeed fortunate that although

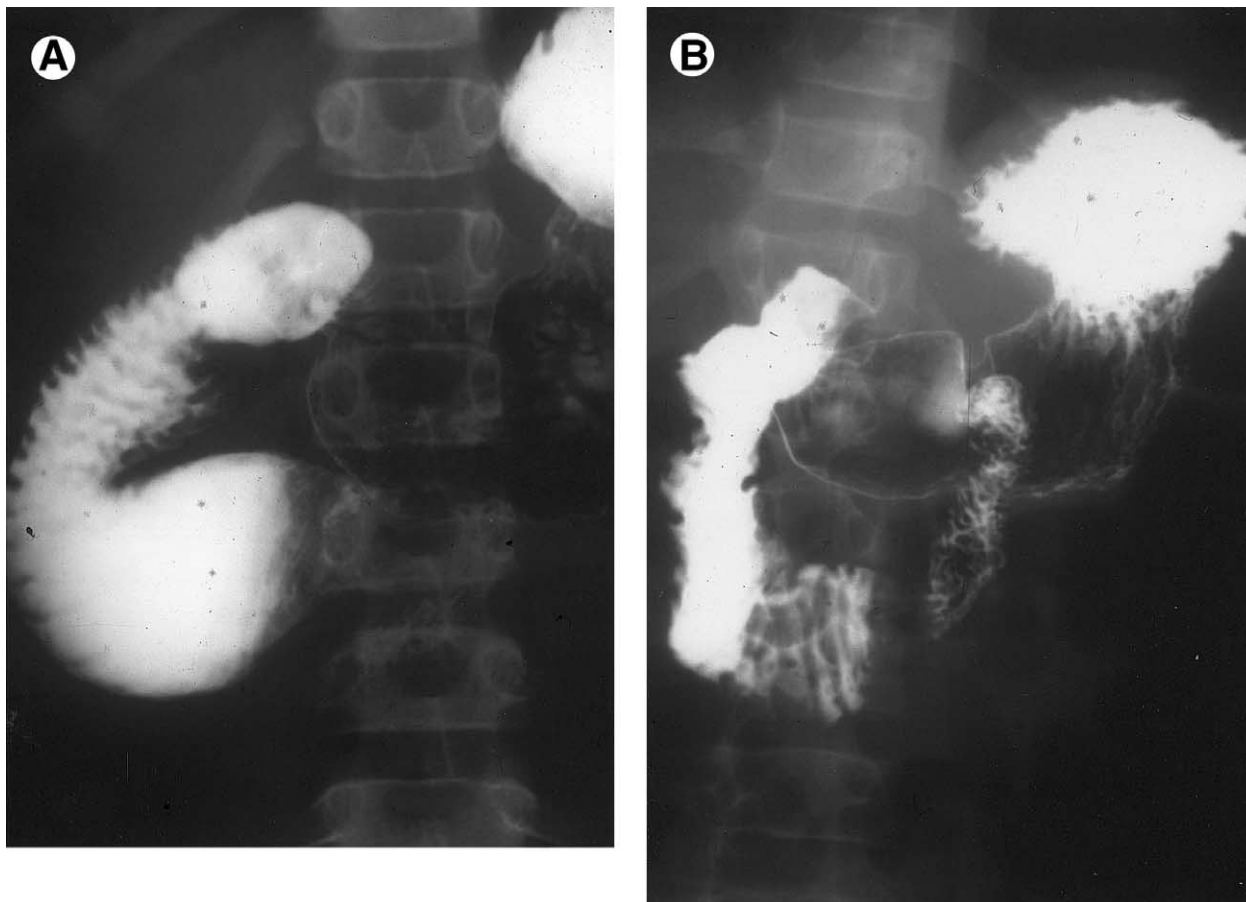


Fig 5. Contrast meal of an 8-year-old girl with a longstanding history of intermittent bilious vomiting. (A) Note the distended third part of duodenum with obstruction. To-and-fro peristalsis was seen on fluoroscopy. (B) After some delay, contrast is seen in the fourth part showing normal rotation and a vertical linear impression suggestive of superior mesenteric artery syndrome (Wilkie syndrome). Duodenojejunostomy resulted in complete resolution of symptoms. It is unwise to attempt derotation and fixation as considerable morbidity from duodenal dysfunction can be expected as observed by the late Prof. J.H. Louw on long-term follow-up of some of his cases.³⁵

midgut volvulus may be present, strangulation at the time of surgery is evident in only about 15% of cases. Mortality from malrotation and midgut volvulus is significantly worse when associated with other congenital anomalies, particularly when cardiac anomalies are present.¹⁰

SURGICAL MANAGEMENT

Ladd's procedure of derotation of the bowel if torsion is present, division of the peritoneal attachments lying across the duodenum from cecum to right upper quadrant, taking down of the ligament of Treitz and moving the duodenum to the right, separation of any adhesions between bowel loops, and, finally, returning the bowel to a position of nonrotation with the cecum placed into the left upper quadrant, is sufficient in most cases. Removal of the appendix is favored by most but is not necessary as long as the parents understand the new site of the

appendix.^{5,15} Laparoscopic management has been successfully performed in selected cases.⁸ There is no need to apply any fixation sutures, as adhesions and the broad base to the mesentery developed by the Ladd's procedure usually stabilize the bowel.^{14,16,31,32} Recurrence is rare but has been seen and may be due to division of the Ladd's bands without a full derotation and splaying of the mesentery.³³ However, adhesive obstruction is not uncommon and requires surgical management in most cases.³² If ischemic bowel is found at laparotomy for volvulus, every attempt should be made to preserve bowel length and if any doubt exists about viability, a second-look laparotomy should be done 24 hours later without initial resection or with very conservative resection. Remarkable recovery has been documented.

Some degree of nonrotation or malrotation is invariably encountered when repairing abdominal wall defects and diaphragmatic hernias but subsequent volvulus is

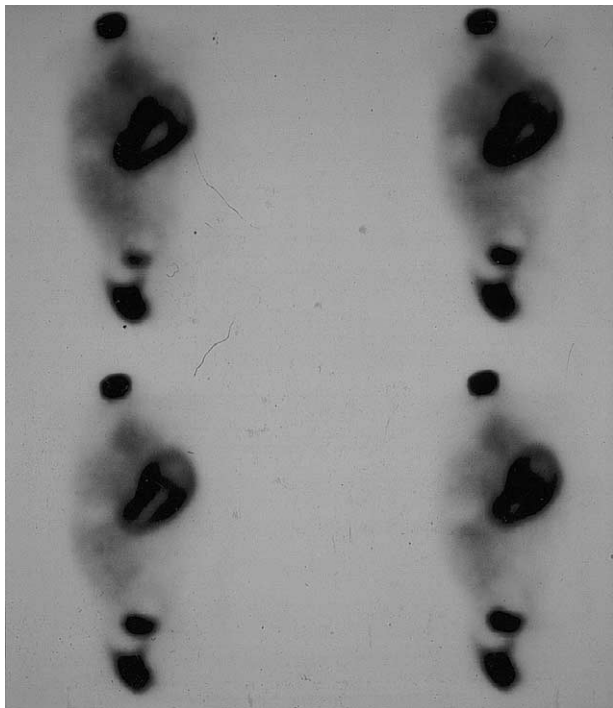


Fig 6. Technetium ^{99m}M scan showing intense uptake in the central abdomen from venous congestion and lymphatic obstruction due to a chronic 270-360° midgut volvulus.

rare.³⁴ Although recommended by some, it is not our practice to perform a concomitant derotation procedure.³⁴ There remains considerable controversy over how the “asymptomatic” patient with a malrotation should be managed.² Attempts to better define the exact nature of the abnormality and length of the base of the mesentery by contrast enema and simultaneous upper gastrointestinal contrast study and even ultrasound, remain unconvincing.^{9,25} Perhaps this is where laparoscopy may have an important role to play. As there may be considerable morbidity from an “unnecessary” Ladd’s procedure, this procedure should not be embarked upon lightly.^{33,35} On the other hand, failure to respond to radiographic evidence of malrotation could be considered malpractice if volvulus was to occur subsequently.

The diagnosis of malrotation and volvulus should always be kept in mind when assessing any infant or child with symptoms of vomiting and pain, particularly when the vomiting is bile-stained. The diagnosis cannot be excluded if diarrhea is present, when clinical findings are bland, or even with normal abdominal radiographs. A contrast meal and follow through should be done and, if correctly interpreted, should be diagnostic.²² Ultrasound examination may be helpful but is not secure enough to exclude the diagnosis. Laparotomy or laparoscopy is the only way to be sure. Malrotation with its propensity for volvulus is truly a time bomb lying within.

REFERENCES

- Filston HC, Kirks DR: Malrotation—the ubiquitous anomaly. *J Pediatr Surg* 16:614-620, 1981
- Newman BM, Auriemma AM: Variation in evaluation and management of malrotation with midgut volvulus (Abstract). American Academy of Pediatrics, Section on Surgery, Program for Scientific sessions: Session 3, No. 2:70-71, 2002
- Mall FP: Development of the human intestine and its position in the adult. *Johns Hopkins Hosp B* 9:197-208, 1898
- Dott NM: Anomalies of intestinal rotation: their embryology and surgical aspects with report of 5 cases. *Br J Surg* 11:251-286, 1923
- Ladd WE: Congenital obstruction of the duodenum in children. *N Engl J Med* 206:277-283, 1932
- Waugh GEA: The morbid consequences of a mobile ascending colon. *Br J Surg* 7:343, 1920
- Prarcos D, Sann L, Gein G, et al: Ultrasound diagnosis of midgut volvulus: the whirlpool sign. *Pediatr Radiol* 22:18-20, 1992
- Gross E, Chen MK, Lobe TE: Laparoscopic evaluation and treatment of intestinal malrotation in infants. *Surg Endosc* 10:936-937, 1996
- Schey WL, Donaldson JS, Sty JR: Malrotation of bowel: variable patterns with different surgical considerations. *J Pediatr Surg* 28:96-101, 1993
- Messineo A, MacMillan JH, Palder SB, Filler RM: Clinical factors affecting mortality in children with malrotation of the intestine. *J Pediatr Surg* 27:1343-1345, 1992
- Reyes J, Bueno J, Kocoshis S, et al: Current status of intestinal transplantation in children. *J Pediatr Surg* 33:243-254, 1998
- Cywes S, Millar AJW: Embryology and Anomalies of the Intestine. *Bockus Gastroenterology* (ed 5). Philadelphia, PA, WB Saunders, 1995, pp 899-929
- Kluth D, Kaestner M, Tibboel D, Lambrecht W: Rotation of the gut: fact or fantasy. *J Pediatr Surg* 30:448-453, 1995
- Millar AJW, Rode H, Brown RA, Cywes S: The deadly vomit: malrotation and midgut volvulus. *Pediatr Surg Int* 2:172-176, 1987
- Ladd WE: Surgical diseases of the alimentary tract in infants. *N Engl J Med* 215:705, 1936
- Maxson RT, Franklin PA, Wagner CW: Malrotation in the older child: surgical management, treatment and outcome. *Am Surg* 61:135-138, 1995
- Brereton RJ, Taylor B, Hall CM: Intussusception and intestinal malrotation in infants: Waugh’s syndrome. *Br J Surg* 73:55-57, 1986
- Breckon VM, Hadley GP: Waugh’s syndrome: a report of six patients. *Pediatr Surg Int* 16:370-373, 2000
- Powell DM, Othersen HB, Smith CD: Malrotation of the intestines in children: the effect of age on presentation and therapy. *J Pediatr Surg* 24:777-780, 1989
- Spigland N, Brandt ML, Yazbeck S: Malrotation presenting beyond the neonatal period. *J Pediatr Surg* 25:1139-1142, 1990
- Louw JH, Barnard CN: Congenital intestinal atresia: observations on its origin. *Lancet* 2:1065-1067, 1955
- Simpson AJ, Leonidas JC, Krasma IH, Becker JM, Schneider KM: Roentgen diagnosis of midgut malrotation: value of upper gastrointestinal radiographic study. *J Pediatr Surg* 7:243-252, 1972
- Usmani SS, Kenigsberg: Intrauterine volvulus without malrotation. *J Pediatr Surg* 26:1409-1410, 1991

24. Dufour D, Delaet MH, Dassonville M, Cadranel S, Perlmutter N: Midgut malrotation, the reliability of sonographic diagnosis. *Pediatr Radiol* 22:21-23, 1992
25. Ashley LM, Allen S, Teele RL: A normal sonogram does not exclude malrotation. *Pediatr Radiol* 31:354-356, 2001
26. Kullendorf CM, Mikaelsson C, Ivancev K: Malrotation in children with symptoms of gastrointestinal allergy and psychosomatic abdominal pain. *Acta Paediatr Scand* 74:296-299, 1985
27. Coombs RC, Buick PG, Gornall PG, Corkery JJ, Booth IW: Intestinal malrotation: the role of small intestinal dysmotility in the cause of persistent symptoms. *J Pediatr Surg* 26:553-556, 1991
28. Kumar D, Brereton RJ, Spitz L, et al: Gastro-oesophageal reflux and intestinal malrotation in children. *Br J Surg* 75:533-535, 1988
29. Nair R, Hadley GP: Intestinal malrotation—experience with 56 patients. *S Afr J Surg* 34:73-76, 1996
30. Spitz L, Orr JD, Harries JT: Obstructive jaundice secondary to chronic midgut volvulus. *Arch Dis Child* 58:383-385, 1983
31. Schwartz DL, So HB, Schneider KM, Becker JM: Recurrent chylous ascites associated with intestinal malrotation and lymphatic rupture. *J Pediatr Surg* 18:177-179, 1983
32. Stauffer UG, Hermann P: Comparison of late results in patients with corrected intestinal malrotation with and without fixation of the mesentery. *J Pediatr Surg* 15:1, 1980
33. Brennon WS, Bill AH: Prophylactic fixation of the intestine for midgut non-rotation. *Surg Gynecol Obstet* 138:181-184, 1974
34. Rescorla FJ, Shedd FJ, Grosfeld JL, Vane DW, West KW: Anomalies of intestinal rotation in childhood: anomalies of 447 cases. *Surgery* 108:710-716, 1990
35. Louw JH: Intestinal malrotation and duodenal ileus. *J R Coll Surg Edinb* 5:101-126, 1960